



Ultrasound for Suspected Appendicitis Protocol

Purpose

To utilize ultrasound for a suspected appendicitis for the pediatric population

Policy

Ultrasound should be the first choice for imaging the pediatric patient with a suspected appendicitis

Population Covered

Pediatric patients with a suspected appendicitis

Responsible Persons

Ordering providers assessing a pediatric patient for suspected appendicitis

Definitions

CT – Computed Tomography. A medical imaging procedure that uses ionizing radiation to produce cross-sectional images of internal organs and body structures.

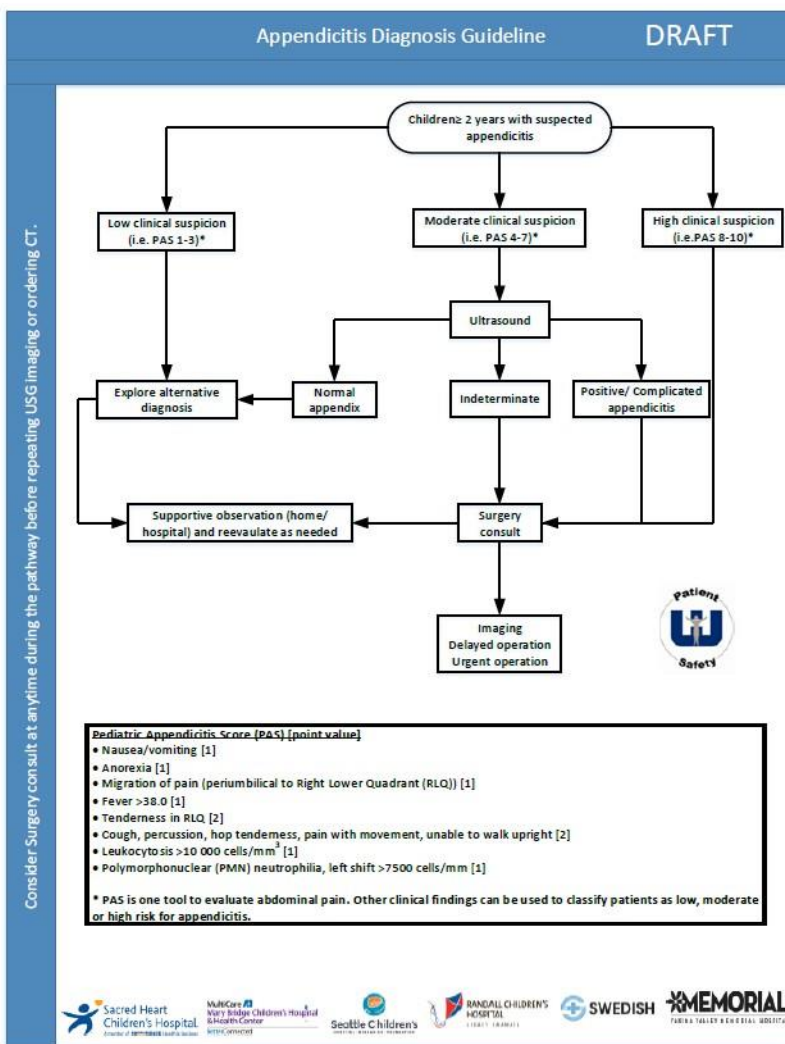
Cross-Sectional Images – A technique used in CT to produce images in a sectional plane through the body to view internal organs and structures.

Ultrasound – A medical imaging device that uses ultrasonic frequencies to produce images of internal body structures.

Content

GENERAL

1. For the pediatric population, it is critical to reduce exposure to undue radiation. The Washington State Hospital Association (WSHA) has established a patient safety protocol for utilizing Ultrasound as the first method of imaging instead of CT for pediatric patients with a suspected appendicitis.
2. Ordering physician should evaluate the pediatric patient and determine if there is a high suspicion for appendicitis.
3. If there is a suspicion for appendicitis, follow the algorithm below:

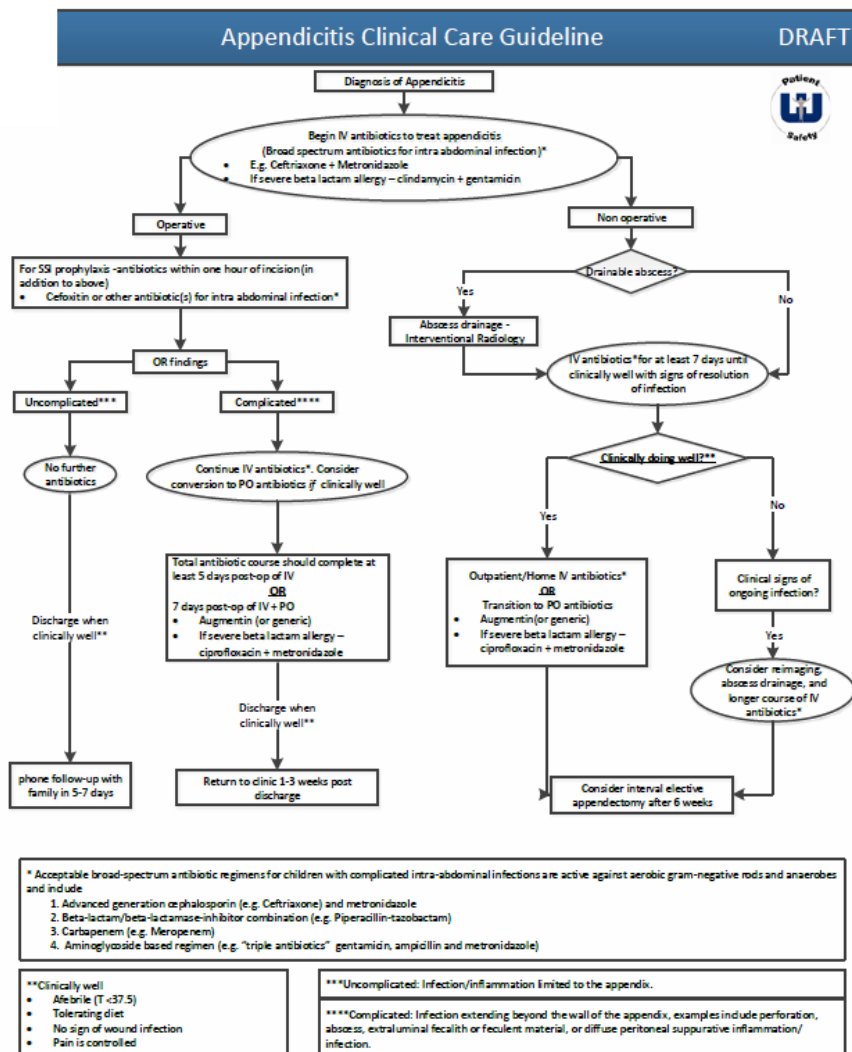


4. If appendicitis is confirmed by ultrasound, the following clinical care guideline should be followed:

Considerations

The protocol is designed to manage the care of pediatrics with suspicion for appendicitis. In order for the protocol to be implemented, a number of elements must be in place for appropriate delivery of care for the pediatric population. The following are examples where the protocol may not be used.

- 1) Ultrasound sonographers are not on-site 24 hours a day
- 2) Ultrasound sonographers are not appropriately trained for imaging of the appendix
- 3) The reading radiologists has little experience interpreting Ultrasound images of the appendix.¹



References

1. <http://www.epmonthly.com/features/current-features/ultrasound-first-in-suspected-appendicitis/>